

Descemet stripping automated endothelial keratoplasty (DSAEK) versus repeat penetrating keratoplasty (PKP) to manage eyes with failed corneal graft

Abdulrahman Khairallah

From the Department of Ophthalmology, King Khalid University, Abha, Saudi Arabia

Correspondence: Dr. Abdulrahman Khairallah · King Khalid University, Abha 62527, Saudi Arabia · M: +966504739331 · dr.akhairallah@gmail.com · ORCID: <http://orcid.org/0000-0002-6302-0987>

Ann Saudi Med 2018; 38(1): 36-41

DOI: 10.5144/0256-4947.2018.36

BACKGROUND: Failed corneal graft management is a challenge. Descemet stripping automated endothelial keratoplasty (DSAEK) and repeat penetrating keratoplasty (PKP) are two options. Only two studies have compared outcomes of DSAEK and PKP in the management of a failed graft.

OBJECTIVE: To compare the visual outcomes, changes in intraocular pressure (IOP) and complications in eyes with failed corneal grafts that were subsequently managed with DSAEK and PKP.

DESIGN: Retrospective cohort study.

SETTINGS: Tertiary eye hospital of central Saudi Arabia.

PATIENTS AND METHODS: A retrospective chart review was performed for cases managed between 2007 and 2012. Data were collected on the best-corrected visual acuity (BCVA) before and at day 1, 1 week, 4 weeks, 12 weeks, and 24 weeks after intervention. BCVA was compared in patients managed with DSAEK or PKP. Intra- and postoperative complications were compared in both groups.

MAIN OUTCOME MEASURES: Clear graft, vision at last follow up, complications.

RESULTS: There were 15 eyes in the DSAEK group and 30 in the PKP group. The causes of previously failed PKP differed between groups. BCVA at 6 months after repeat surgeries was 20/20 to 20/40 in 4 (27%) eyes in the DSAEK group and in 8 (27%) eyes in the PKP group. The IOP at 6 months was statistically significantly higher in the DSAEK group than the PKP group ($P=.006$). In DSAEK group, one graft rejection occurred in one eye and graft dislocation in another eye. Seven eyes in PKP group had signs of graft rejection that regressed in 5 eyes following medical management.

CONCLUSIONS: DSAEK and PKP for previously failed corneal graft resulted in similar BCVA 6 months after repeat surgery. However, the visual outcomes were less promising with both types of surgeries. The lower complication rate and surgical ease may favor DSAEK over PKP in managing failed grafts.

LIMITATIONS: Small sample, retrospective study.

Penetrating keratoplasty (PKP) was the primary procedure with promising visual outcomes for many corneal diseases in the past.^{1,2} However, the graft rejection rate was as high as 29% with this procedure.³ Descemet stripping automated endothelial keratoplasty (DSAEK) was introduced as an alternative procedure for endothelial diseases with debatable benefits over PKP. Researchers found more favorable outcomes with DSAEK over PKP in the management

of failed PKP.^{3,4} However, a Cochrane review found that clinical trials did not show confirmatory evidence in PKP.⁴ During surgery, the eye is opened posing risk of hypotony and infection. In DSAEK, endothelium is inserted in the anterior chamber through a small opening and the endothelium is then manipulated to settle on the posterior surface of the cornea. Since no sutures are placed, postoperative suture-related discomfort and risk of infection is also less in the latter procedure.

However, the issue is more complex when dealing with failed grafts. A number of articles have been published on the role of keratoplasty in treating failed graft.^{4,5} Due to scarcity of donor material in Arab countries and a higher rate of complications after performing PKP again on an eye with a first failed graft, surgeries like DSAEK and Descemet membrane automated endothelial keratoplasty (DMAEK) are alternatives. In the former procedure only peeled endothelium is transplanted. In DMAEK, the anterior portion of the cornea is removed and the Descemet membrane and endothelium are transplanted. This provides better stability and less endothelial loss after surgery. Additionally, DSAEK and DMAEK have shown more promising visual outcomes and fewer complications.^{6,7} A comparison of these methods as a primary procedure was performed by Bahr et al.⁸ However, to the best of our knowledge, only two studies by Ang et al⁹ and Kitzmann et al,¹⁰ compared outcomes of DSAEK and PKP in the management of a failed graft. In this retrospective study, we compared success rates by visual outcomes, clarity of graft at last follow up and complications of repeat PKP or DSAEK for failed corneal graft in Saudi Arabian patients.

PATIENTS AND METHODS

A retrospective chart review was performed of patients with failed corneal graft after PKP who underwent subsequent DSAEK and PKP between January 2007 and December 2012 at the cornea unit of King Khaled Eye Specialist Hospital (KKESH), Riyadh, Saudi Arabia. The institutional research board of KKESH approved this study. Consent was waived because this was a review of health records. Strict anonymity of patient data was maintained for the duration of this study.

We assumed that the best-corrected visual acuity (BCVA) after DSAEK in eyes with failed PKP would be 20/40 or better in 70% of eyes and BCVA would be 20/40 or better in 40% of eyes treated by repeat PKP.⁵ For a 1:2 ratio of DSAEK and PKP group, 15 eyes were required in DSAEK and 30 eyes in the PKP group to achieve 95% confidence interval and 80% power study to test a one-sided hypothesis.

One cornea subspecialist and one medical student performed the chart review. The demographic variables collected included age, sex and laterality. Data were collected on systemic diseases such as hypertension, diabetes and hyperlipidemia. Ocular data were collected for primary PKP, duration between graft rejection and the repeat keratoplasty, and number of surgeries performed in eyes with failed graft prior to the current intervention. The presenting vision (UCVA) and the best corrected vision (BCVA) were tested with a Snellen

distance vision chart positioned 6 meters from the patient. The intraocular pressure (IOP) was measured with a Tono-Pen device (Heine Optotechnik, Herrsching, Germany). The surgery details included the date of surgery, type of surgery, intraoperative complications and sutures. Postoperative follow up was performed at day 1, 1 week, 4 weeks, 12 weeks, and 24 weeks after intervention.

The main outcome was the BCVA at 6 months postoperatively. It was further categorized as normal functional vision (20/20 to 20/40), moderate visual impairment (20/50 to 20/200) severe visual impairment (<20/200). The other outcomes were IOP at follow up and clarity of the graft.

The data were compiled on a Excel spreadsheet (Microsoft Corp., Redmond, WA, USA). The data were transferred to IBM SPSS version 22 (Armonk, New York, USA). Univariate analysis was performed on categorical variables to estimate frequencies and percentage proportions. For quantitative variables, normality was checked to select the type of analysis (parametric vs nonparametric). We compared the outcome variables for DSAEK and PKP groups with a two-sided P value using the Mann Whitney U test (for non-normal distribution). Statistical significance was set at $P < .05$.

RESULT

Fifteen eyes were managed by DSAEK and 30 eyes by PKP (**Table 1**). There were more cases of bullous keratopathy in the DSAEK group and more cases of keratoconus in the PKP group.

The visual status preoperatively, best vision postoperatively and on the last follow up visit of both groups are compared in **Table 2**. Patients who were lost to follow up were considered to have poor vision. At 24 weeks, the vision was 20/20 to 20/40 in 4 (27%) eyes of DSAEK group and in 8 (27%) eyes of PKP group. DSAEK restored vision to better than 20/200 in 12 (80%) eyes. PKP improved vision to better than 20/200 in 23 (77%) eyes. Many cases in the PKP group prior to current intervention were blind (vision <20/400).

The changes in IOP in eyes undergoing DSAEK before and 6 months after the procedure are presented in **Figure 1A**. For PKP, IOS was only measured 6 months after the procedure (**Figure 1B**). The cases that had undergone PKP in the past and had developed corneal complications and the IOP before scheduled repeat PKP could not be taken prior to second surgery. The IOP at 6 months in the DSAEK group was statistically significantly higher than that of PKP group ($P = .006$). In DSAEK group, two eyes had IOP >22 mm Hg at 24 weeks. In the PKP group, no eye had IOP greater than 22 mm

Table 1. Profile of eyes with failed penetrating keratoplasty managed by Descemet stripping automated endothelial keratoplasty (DSAEK) and repeat penetrating keratoplasty (PKP).

		DSAEK group (n=15)		PKP group (n=30)		Two-sided P value
Age (years)	Mean (SD)	60.9 (15.7)		52.3 (22.9)		.1
Interval between graft failure and current intervention	Median	4.9		2.5		.01
	25% quartile	3.5		1.2		
	Minimum, maximum	1.8, 25.3		0.1, 33.3		
Gender	Male	7	47	19	63	.3
	Female	8	53	11	37	
Eye involved	Right eye	4	27	14	47	.2
	Left eye	11	73	16	53	
Indication for repeat corneal grafting (failed)	Bullous keratopathy	6	40	1	3	.07
	Keratoconus	1	7	5	17	
	Corneal scar	2	13	5	17	
	Trauma and other	5	33	9	30	
Surgeries in the past (keratoplasty, cataract, glaucoma)	Missing	1	7	10	33	.04
	One	12	80	19	63	
	Two	2	13	6	20	
	3 and more	1	7	5	17	
BCVA before present intervention	20/20 to 20/40	0	0	1	3	.4
	<20/50 to 20/200	2	13	7	23	
	<20/200 to 20/400	13	87	4	13	
	<20/400	0	0	18	60	

For age we used t test. For interval between graft failure and current intervention, we used the Mann Whitney U test. For gender and eye involved we used 2x2 table to calculate a two-sided P value with significance level of <.05. For indications for surgery, failed surgery in past and pre-intervention BCVA, we used chi-square value, degree of freedom and two-sided P values as significant.

Hg at 24 weeks (at 90% CI). Glaucoma comorbidity was the cause of poor gain in vision in 2 (13%) eyes in the DSAEK group and 3 (10%) eyes in PKP group.

In the DSAEK group, lenticule was detached in two eyes, one eye (6.7%) had a graft rejection and another one (6.7%) had a graft dislocation. In the PKP group, one eye had early signs of graft rejection (like corneal haze, increased corneal vascularization, endothelial thickening), and six eyes had graft-related complications warranting intervention. Signs of graft rejection

regressed in five eyes following medical management. They were given prednisolone acetate 1% (predForte) eye drop every 1 hour for 2 days. then tapered according to the response.

DISCUSSION

The visual outcomes following DSAEK and PKP six months after managing a failed graft were not significantly different in our study. The graft rejection rate in DSAEK group was lower than PKP. The IOP at 6 months

Table 2. Uncorrected visual acuity (UCVA) before and following surgery to manage failed keratoplasty.

	DSAEK			Repeat PKP		
	Preoperative VA	Best postoperative VA	Last postoperative VA	Preoperative VA	Best postoperative VA	Last postoperative VA
20/20 to 20/40	0	1	1	0	3	2
20/50 to 20/120	6	5	3	1	17	6
20/200 to CF	5	4	3	21	8	5
HM	2	1	0	8	0	1
PL	2	0	0	0	0	0
No PL	0	0	0	0	0	0
Unknown	0	4	8	0	2	16
Total	15	15	15	30	30	30

VA: visual acuity. Perception of light (PL) in the eye affected is defined as PL present or PL absent.

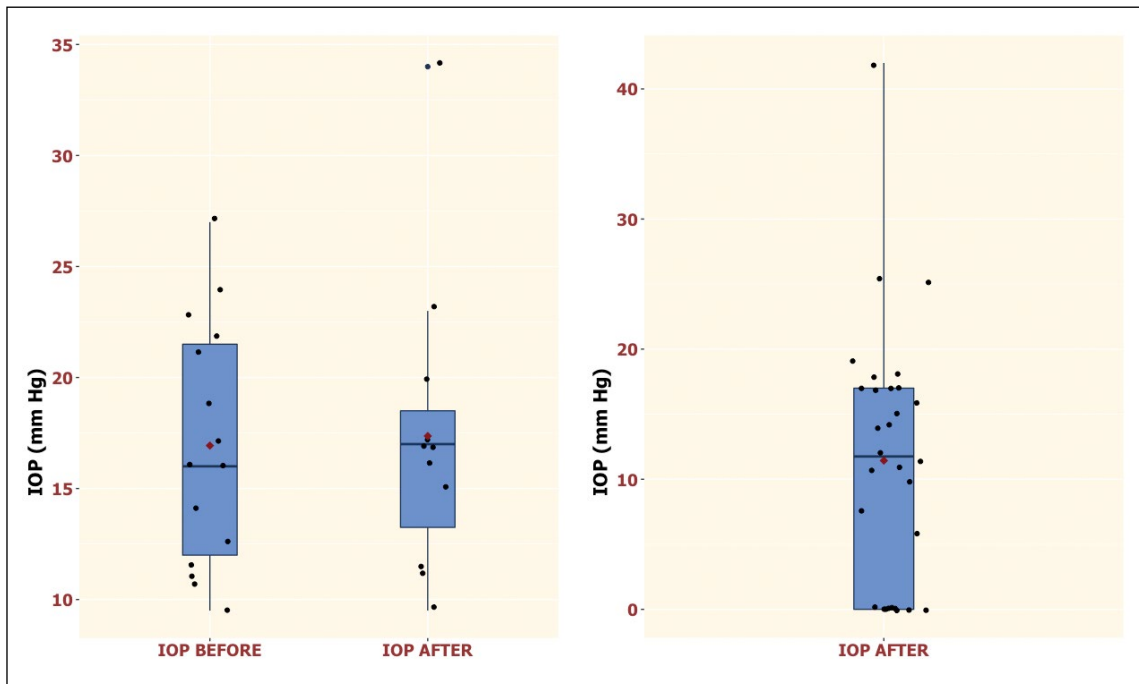


Figure 1. Intraocular pressure in eyes with failed graft before and 6 months after management by Descemet stripping automated endothelial keratoplasty (DSAEK) (n=15) (Left) and 6 months after management by repeat penetrating keratoplasty (PKP) (n=30) (Right). The IOP at 6 months was statistically significantly higher in the DSAEK group than the PKP group ($P=.006$) (Mann-Whitney U test). (Box plot: median, lower and upper hinges correspond to the first and third quartiles [25th and 75th percentiles]. The upper whisker extends from the hinge to the largest value no further than $1.5 * IQR$ from the hinge, where IQR is the interquartile range, or distance between the first and third quartiles. The lower whisker extends from the hinge to the smallest value at most $1.5 * IQR$ of the hinge. Data beyond the end of the whiskers are "outlying" points plotted individually. Red diamond is mean).

in DSAEK group was statistically significantly higher than PKP group. The complications in the DSAEK group were lower than in the PKP group.

The eyes undergoing repeat graft following graft

failure had less promising results compared to primary grafting. However, the results were similar between groups undergoing DSAEK or PKP. In another study, the percentage of endothelial loss 1 year after PKP

was 22% (n=34).¹¹ The median postoperative vision was 20/40 six months after primary DSAEK.¹² However, DSAEK in failed graft resulted in anatomic success in 75% of cases with few complications and a high level of surgeon satisfaction.¹³

Eyes with failed PKP with compromised status before repeat PKP had less promising visual outcomes at last follow up at 2 years. However, postoperatively, many patients had good functional vision after 6 months in the current study. A previous study reported that in cases of repeat PKP for a failed graft, the vision was 20/20 to 20/40 in 44% of eyes at 2 years postoperatively and graft failure rate was 11% within six months postoperatively.¹⁴ A comparative study reported that postoperative vision ranging from 20/20 to 20/40 in a DSAEK group was 80% compared to only 18% in repeat PKP group for managing failed graft.¹⁰ However Kitzmann et al¹⁰ only evaluated seven eyes after 3 years in the DSAEK group, which could explain the large variation in visual success between groups.

In our study, the graft rejection rate in PKP and DSAEK group was 7% and 23%, respectively. However, with medical management, rejection signs were reversed in five eyes in the DSAEK group. A multi-centered study that enrolled a large cohort suggested that the failure rate of repeat DSAEK graft following failed PKP evaluated at a median follow up period of 17 months was 19%.¹⁵ The rate of graft rejection of PKP in eyes with keratoconus was 41% in first 2 years.¹⁶ In our study, five eyes had keratoconus in the PKP group and only one case of keratoconus in the DSAEK group. Thus, the cases with failed graft perhaps are less suitable for DSAEK and therefore comparison of PKP to DSAEK must account for the original indication for keratoplasty. In the present study also, keratoconus was the underlying pathology in 5 eyes in the PKP group and in 1 eye in the DSAEK group.

In our study, there was no significant difference in rate of glaucoma after PKP and DSAEK. Even eyes with glaucoma that were being treated did not have raised IOP at 24 weeks following PKP. This contrasts with the risk of glaucoma in the literature. One episode of raised intraocular pressure was noted in more than half of the eyes that underwent PKP.¹⁷ Even after DSAEK, development of glaucoma has been documented.¹⁸

The dislocation of the lenticule is a known but easily manageable complication in eyes undergoing DSAEK.

In our study, lenticule dislocation occurred in two (13%) eyes. In an Iranian study, the lenticule dislocation rate was 22% following DSAEK by cornea fellows.¹⁹ A study in the US noted a 36.6% rate of graft dislocation following DSAEK that was managed by rebubbling.²⁰ Since all DSAEK were performed by a cornea surgeon and only five PKP were done by fellows, it is difficult to relate the role of operating surgeon in differential outcomes in two procedures in our study. It seems that this complication was less prevalent in our study compared to other studies. However, this should be interpreted with caution in view of small sample size.

The outcomes of keratoplasty in Saudi Arabia are less promising than noted in studies from industrialized countries both for failed PKP and primary PKPs. Vision from 20/20 to 20/40 was achieved in 40% of cases managed by PKP in a study in a private hospital in Saudi Arabia.²¹ Postoperative visual acuity of 20/20 to 20/40 was noted in 68% of 311 eyes with keratoconus that had undergone primary PKP.²² This rate further declined when PKP was performed to manage failed graft with functional vision in only 4.8% of eyes.²³ The learning curve among postgraduate students at our teaching institute could be an alternative explanation of lower outcomes with PKP. It could also be due to presence of other comorbidities, noncompliance to adherence to medical advices, and other reasons. DSAEK performed by cornea fellows under supervision of faculty members have shown fairly acceptable results in Iran.¹⁹

An indicator of success after keratoplasty is the endothelial status of the graft. Unfortunately, we did not have data on any specular microscopy for either group. Further studies are recommended to study the endothelial status and graft survival in DSAEK and PKP for failed grafts.

The primary objective in failed graft management seems to be anatomical restoration of ocular status (clear corneal graft) and avoiding phthisis or high IOP. Restoration of vision depends on the graft clarity as well as the presence of other comorbidities. A tertiary eye institution, which must manage all complex cases, is more likely to receive failed graft cases with other ocular diseases. That may be the underlying reason for more frequent compromised vision even after successful graft surgery. In addition, the small, retrospective sample is the principal limitation of our study.

REFERENCES

1. Sun YJ, Li AP, Pan ZQ, Luo F, Zou LH. Systematic review of penetrating keratoplasty rejection treated by immunosuppressants. *Zhonghua Yan Ke Za Zhi*. 2010;46(12):1122-7.
2. Joshi SA, Jagdale SS, More PD, Deshpande M. Outcome of optical penetrating keratoplasties at a tertiary care eye institute in Western India. *Indian J Ophthalmol*. 2012;60(1):15-21.
3. Den S, Kawashima M, Shimmura M, Imai Y, Satake Y, Shimazaki J. How good is transplantation of corneal parts compared with penetrating keratoplasty? *Cornea*. 2010;29(Suppl 1):S48-51.
4. Nanavaty MA, Wang X, Shortt AJ. Endothelial keratoplasty versus penetrating keratoplasty for Fuchs endothelial dystrophy. *Cochrane Database Syst Rev*. 2014;(2):CD008420.
5. Covert DJ, Koenig SB. Descemet stripping and automated endothelial keratoplasty (DSAEK) in eyes with failed penetrating keratoplasty. *Cornea*. 2007;26(6):692-6.
6. Price FW Jr, Price MO. Endothelial keratoplasty to restore clarity to a failed penetrating graft. *Cornea*. 2006;25(8):895-9.
7. Chih A, Lugo M, Kowing D. Descemet stripping and automated endothelial keratoplasty: an alternative to penetrating keratoplasty. *Optom Vis Sci*. 2008;85(3):152-7.
8. Bahar I, Kaiserman I, Levinger E, Sansanayudh W, Slomovic AR, Rootman DS. Retrospective contralateral study comparing descemet stripping automated endothelial keratoplasty with penetrating keratoplasty. *Cornea*. 2009;28(5):485-8.
9. Ang M, Ho H, Wong C, Htoon HM, Mehta JS, Tan D. Endothelial keratoplasty after failed penetrating keratoplasty: an alternative to repeat penetrating keratoplasty. *Am J Ophthalmol*. 2014;158(6):1221-7.
10. Kitzmann AS, Wandling GR, Sutphin JE, Goins KM, Wagoner MD. Comparison of outcomes of penetrating keratoplasty versus Descemet's stripping automated endothelial keratoplasty for penetrating keratoplasty graft failure due to corneal edema. *Int Ophthalmol*. 2012;32(1):15-23.
11. Patel SV, Hodge DO, Bourne WM. Corneal endothelium and postoperative outcomes 15 years after penetrating keratoplasty. *Trans Am Ophthalmol Soc*. 2004;102:57-65.
12. Khor WB, Han SB, Mehta JS, Tan DT. Descemet stripping automated endothelial keratoplasty with a donor insertion device: clinical results and complications in 100 eyes. *Am J Ophthalmol*. 2013;156(4):773-9.
13. Zitte K, Bonnin N, Kémény JL, Bacin F, Mulliez A, Chiambaretta F. DSAEK after failed penetrating keratoplasty. *J Fr Ophthalmol*. 2015;38(1):22-33.
14. Patel NP, Kim T, Rapuano CJ, Cohen EJ, Laibson PR. Indications for and outcomes of repeat penetrating keratoplasty, 1989-1995. *Ophthalmology*. 2000;107(4):719-24.
15. Mitry D, Bhogal M, Patel AK, Lee BS, Chai SM, Price MO, et al. Descemet stripping automated endothelial keratoplasty after failed penetrating keratoplasty: survival, rejection risk, and visual outcome. *JAMA Ophthalmol*. 2014;132(6):742-9.
16. Niziol LM, Musch DC, Gillespie BW, Marcotte LM, Sugar A. Long-term outcomes in patients who received a corneal graft for keratoconus between 1980 and 1986. *Am J Ophthalmol*. 2013;155(2):213-9.
17. Oruçoglu F, Blumenthal EZ, Frucht-Pery J, Solomon A. Risk factors and incidence of ocular hypertension after penetrating keratoplasty. *J Glaucoma*. 2014;23(9):599-605.
18. Banitt MR, Chopra V. Descemet's stripping with automated endothelial keratoplasty and glaucoma. *Curr Opin Ophthalmol*. 2010;21(2):144-9.
19. Hashemi H, Asghari H, Amanzadeh K, Behrooz MJ, Beheshtnejad A, Mohammadpour M. Descemet stripping automated endothelial keratoplasty performed by cornea fellows. *Cornea*. 2012;31(9):974-7.
20. Heitor de Paula F, Kamyar R, Shtein RM, Sugar A, Mian SI. Endothelial keratoplasty without Descemet stripping after failed penetrating keratoplasty. *Cornea*. 2012;31(6):645-8.
21. Omar N, Bou Chacra CT, Tabbara KF. Outcome of corneal transplantation in a private institution in Saudi Arabia. *Clin Ophthalmol*. 2013;7:1311-8.
22. Al-Mohaimeed MM. Penetrating keratoplasty for keratoconus: visual and graft survival outcomes. *Int J Health Sci (Qassim)*. 2013;7(1):67-74.
23. Al-Mezaine H, Wagoner MD. King Khaled Eye Specialist Hospital Cornea Transplant Study Group. Repeat penetrating keratoplasty: indications, graft survival, and visual outcome. *Br J Ophthalmol*. 2006;90(3):324-7.