original article

Incidence and outcomes of antenatally detected congenital hydronephrosis

Jameela Abdulaziz Kari,[a] Saddiq Habiballah,[a] Saad A. Alsaedi,[a] Hussain Alsaggaf,[a] Amal Al-dabbagh,[a] Adila AbulHamail,[a] Adel Marzouki,[a] Basem Eldeek[b]

From the [a]Pediatrics, King Abdulaziz University, Jeddah, Saudi Arabia; [b]Community Medicine, King Abdulaziz University, Jeddah, Saudi Arabia

Correspondence: Prof. Jameela Abdulaziz Kari · Pediatrics, King abdulaziz University, PO Box 13042 Jeddah 21943, Saudi Arabia · T: 0505677904 F: 026408353 · jkari@doctors.org.uk

Ann Saudi Med 2013; 33(3): 260-264

DOI: 10.5144/0256-4947.2013.260

BACKGROUND AND OBJECTIVES: Antenatally detected urinary tract abnormalities (ADUTA) are increasingly recognized. Our aims were to determine the incidence and outcomes of antenatally diagnosed congenital hydronephrosis in a large cohort.

DESIGN AND SETTINGS: We recorded the number of total deliveries over 4 years at King Abdulaziz University Hospital (KAUH) between January 2008 and December 2011 from the number of nursery and neonatal intensive care unit (NICU) admissions.

PATIENTS AND METHODS: We reviewed the records of 18 853 deliveries between January 2008 and December 2011 at KAUH, Saudi Arabia. ADUTA were recorded, and their postnatal medical records were reviewed for demographic and radiological data.

RESULTS: ADUTA were diagnosed in 327 fetuses (1.7%). The commonest pathology was congenital hydronephrosis (n=313, 95.7%). Cystic renal anomalies were reported in 4 babies (1.2%), and 10 children (3.1%) were reported to have other renal anomalies, including duplex kidneys or a single kidney. A total of 240 babies with congenital hydronephrosis were followed up. Hydronephrosis resolved in 99 children (41.2%) within 2 months of birth. A total of 29 subjects had underlying renal anomalies (12.1%), including vesicoureteral reflux (n=12, 5%), pelvi-ureteric junction obstruction (n=14, 5.8%), and posterior urethral valve (n=3, 1.3%). The best predictor for nonresolving congenital hydronephrosis and underlying anatomical abnormalities was the anteroposterior diameter on the first postnatal scan. A cut-off point of 5 mm was found to be 83% sensitive in predicting nonresolving hydronephrosis, while 7 mm was 88% sensitive and 10 mm was 94% sensitive.

CONCLUSIONS: Congenital hydronephrosis is the commonest ADUTA. A large percentage resolved within 2 months of birth, but underlying anatomical abnormalities were found in 12.1%. All babies with antenatally detected hydronephrosis should be examined by ultrasound postnatally but further radiological investigations should only be performed for persistent significant AP dilatation ≥10 mm.

Antenatally detected urinary tract abnormalities (ADUTA) are frequently encountered.[1] The recommended postnatal evaluation of these infants has evolved to minimize invasive testing while maximize the detection of significant abnormalities. Recently, many reports have indicated that there is a low rate of detectable renal abnormalities in infants with a normal postnatal sonogram at 4 to 6 weeks of age.[2] More than 50% of cases of antenatally detected hydronephrosis will resolve spontaneously after birth. The other 50% comprises anatomical anomalies that include ureteropelvic junction obstruction (PUJO), vesico-ureteral reflux, and primary megaureters.[3] Postnatal radiological evaluation (renal ultrasonography and voiding cystourethrogram) is performed in every infant with a significantly dilated renal pelvis (>8 mm between 20 and 30 weeks gestation or >10 mm after 30 weeks in utero). A renal nuclear scan should be performed in every child with significant/worsening postnatal hydronephrosis.[4] It is also recommended that the use of micturating cystourethrography (MCUG) should be limited, and this investigation should be delayed until the baby is 3 to 4 months old to allow for the spontaneous resolution of vesicoureteric reflux.[5]

The diagnosis of PUJO is based on the combination of abnormal dynamic renogram [diethylenetetra-

minepentacetic acid (DTPA) or mercaptoacetyltriglycine (MAG3)] findings and a wide pelvic diameter in the absence of ureteric dilatation. It is recommended that pyeloplasty is the appropriate treatment for children with congenital PUJO and <40% split differential function and/or a pelvic diameter >35 mm at the initial investigation. In other patients, a period of observation is warranted, and pyeloplasty should be carried out only if their kidney function deteriorates or the renogram curve does not improve.[6]

Some of the cases with antenatally diagnosed hydronephrosis are subsequently shown antenatally to have a megaureter. Only 30% of these children require surgical correction and reimplantation.[7] A renal function <30%, grade 3 or 4 hydronephrosis, and a ureteric diameter >1.33 cm have been reported as significant and independent predictive factors for surgery.[7]

In this study, we report a single-center experience with ADUTA at King Abdulaziz University hospital (KAUH). We looked at the incidence of ADUTA and we investigated antenatally diagnosed hydronephrosis and find out how many percentage resolved, what percentage were VUR, PUJ or mega-ureters.

PATIENTS AND METHODS

We recorded the number of total deliveries over 4 years at KAUH between January 2008 and December 2011 from the number of nursery and neonatal intensive care unit (NICU) admissions. We examined the number of cases that were previously diagnosed with ADUTA and calculated the prevalence. All children with congenital hydronephrosis were included in the study, and their electronic files as well as those of their mothers were reviewed. We recorded the US finding antenatally and the gestational age (GA) it was performed. The widest pelvic anteroposterior (AP) diameter measurement was recorded from the antenatal US, as well as from all following US studies. The dilatation of the ureters was also recorded on US studies. The results of MCUG and DTPA scans were also recorded. Congenital hydronephrosis was defined as an AP diameter ≥5 mm at any GA.[8] MCUG and DTPA scans were requested if the AP diameter was ≥10 mm on the postnatal US scans. We used DTPA scan as it was the only dynamic renogram available at our hospital; MAG3 was not available. This study was approved by the local ethics committee.

Statistical analysis

The statistical analysis was performed with SPSS, version 16 (SPSS Inc., Chicago, Illinois). The quantitative data were presented in the form of means and standard deviation. The t test of independent samples was used to compare the quantitative data between the 2 groups. Log transformation was performed for nonparametric data. Receiver operating curve was done to determine the sensitivity and specificity of different cut–off points for detecting the hydronephrosis. Significance was considered at *P* values less than .05.

RESULTS

Over 4 years, there were 18 853 deliveries at KAUH with 327 antenatally detected renal abnormalities (1.7% of pregnancies). The majority of cases of ADUTA were congenital hydronephrosis (n=313, 95.7%). Hydronephrosis was bilateral in 177 cases (56.5%) and unilateral in 136 cases (43.5%). Cystic renal anomalies were reported in 4 babies (1.2%), and 10 children (3.1%) were reported to have other renal anomalies, such as duplex kidneys or a single kidney.

Table 1 gives a summary of the demographic data of the babies who were antenatally diagnosed with congenital hydronephrosis. Antenatal US was done at a median of 34 weeks GA (range, 20-41 weeks) and the median AP pelvic diameter was 5.85 mm (range, 4.5-30

Table 1. Demographic and clinical data of patients with antenatally detected congenital hydronephrosis.

	Number (total, n=313)	Percentage (%)
Gender		
Male	231	73.8
Female	82	26.2
Nationality		
Saudi	171	54.6
Non-Saudi	142	45.4
Booking status		
Booked	279	89.1
Unbooked	34	10.9
Gestational age at the antenatal US		
Mean (SD)	33.65 (4.2)	
Median (range)	34 (20-41)	
VUR	12	5%
UPJO	14	5.8%
PUV	3	1.3%

PUV: Posterior urethral valves, SD: standard deviation, UPJO, uteropelvic junction obstruction, US: ultrasound; VUR, vesicoureteral reflux.

Table 2. Time of postnatal ultrasound for babies who had resolution of their hydronephrosis.[a]

Resolved at	Mean (SD)	Median	Range
First US (n=64)	10.68 (9.8)	8	1-56
Second US (n=21)	147 (127)	56	28-728
Third US (n=12)	660 (340)	240	60-3840
Fourth US (n=2)	810 (165)	480	480-1140

US: Ultrasound.

[a]Data are presented in days.

Table 3. Annual incidence of hydronephrosis detected antenally and followed up postnatally with serial ultrasound examinations.

Ultrasound	N	Resolved N (%)	Nonresolved N (%)
First US[a]	240	64 (26.7%)	176 (73.3%)
Second US	102	21 (20.6%)	81 (79.4%)
Third US	38	12 (31.6%)	26 (68.4%)
Fourth US	6	2 (33.3%)	4 (66.6%)

US: Ultrasound.

[a]The first US examination was performed within the first 2 months after birth.

Table 4. Gestational and first postnatal ultrasound measurements for resolved and nonresolved cases of hydronephrosis.

	Resolved	Nonresolved	*P* value
Gestational AP pelvic diameter (mean [SD])	5.84 (1.86)	6.3 (3.1)	.23
First postnatal US AP diameter (mean [SD])	5.48 (3.2)	9.85 (7.52)	< .001

AP: Anteroposterior, SD: standard deviation, US: ultrasound.

mm). A total of 73 subjects were lost to follow-up and were therefore excluded from further analysis.

Only 240 babies were followed up by US at the median age of 8 days (range, 1-56 days); of these, the hydronephrosis had resolved in 64 cases (26.7%). **Table 2** shows the time when postnatal US was performed for babies who had resolution of their hydronephrosis. The annual incidence of hydronephrosis (detected antenally and followed up postnatally with serial ultrasound examinations) is shown in **Table 3**.

A second US was carried out in 102 babies at the median age of 56 days (range, 28-728 days), which revealed that a further 21 (20.6%) cases of hydronephrosis resolved. A further 12 cases of hydronephrosis resolved on the third US at a median age of 240 days (range, 60-384 days) and another 2 babies were found to have resolved hydronephrosis on the fourth US, which was performed after 1 year. Overall, the hydronephrosis resolved in 41.2% (99 babies) of all 240 cases, and the majority (85.8%) resolved within the first 2 months of life. No difference was observed with regard to the rate of resolution between bilateral and unilateral hydronephrosis detected antenatally (P=.52) or on the first postnatal US (0.42).

A total of 60 babies (25%) had an MCUG at a median age of 47 days (range, 14-150 days) and 42 babies (17.5%) had a DTPA scan at a median age of 60 days (range, 7-120 days). Twelve children (5%) were found to have VUR, 14 cases were found to have PUJ obstruction (5.8%), and 3 boys had a posterior urethral valve (PUV; 1.3%). The median AP pelvic diameter in the 29 babies with underlying structural anomalies in the antenatal US was 6 mm (range, 4.55-14 mm). Of these, 10 had bilateral hydronephrosis and 19 had unilateral hydronephrosis, which measured an average of 8 mm (range, 5-49 mm) on the first postnatal US scan.

The best predictor for nonresolving congenital hydronephrosis and underlying anatomical abnormalities was the AP diameter on the first postnatal scan. The cut-off point of 5 mm was found to be 83% sensitive in predicting nonresolving hydronephrosis compared to a sensitivity of 88% for 7 mm and 94% for 10 mm.

We examined the difference in AP pelvic diameter in babies in whom the hydronephrosis resolved and in those who had persistent hydronephrosis (**Figure 1**). No difference was found in the AP diameter measured on the antenatal US, while the difference was highly significant for the AP diameter measured at the first postnatal US (**Table 4**). The mean (SD) cut-off of 5.5 (3.2) mm was associated with resolving congenital hydronephrosis, while 9.85 (7.5) mm was associated with nonresolving congenital hydronephrosis.

DISCUSSION

The rate of antenatally detected renal anomalies determined in this study was 1.7%, which was higher than those reported in previous series of 0.5%-1%.[1,2,7] This was also a higher incidence than those reported from another center in Saudi Arabia, which was 0.7%.[9] This finding could be explained by the low cut-off point of our definition of a wide antenatal AP pelvic diameter of 5 mm, while some other studies considered 7 mm or above to represent dilatation.[10] However, Dudley et al used 5 mm, and reported that the incidence of ADUTA was 0.6%.[8] Data from a large European database for the surveillance of congenital malformations, involving 20

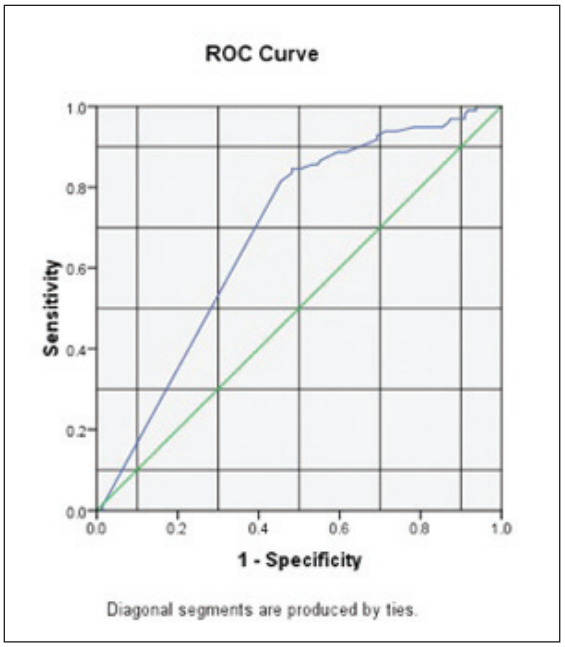

Figure 1. The ROC for the three suggested cut-off points for the AP diameter and the area under the curve (AUC) values are shown in **Table 5**.

Table 5. The sensitivity and specificity of the 3 cut-off points.

Cut-off	Sensitivity	Specificity
5 mm	83%	52%
7 mm	88%	40%
10 mm	94%	22%

participating registries, revealed large regional differences in the prevalence of congenital hydronephrosis, which ranged from 2 to 29 cases per 10 000 births.[10] This data only included babies with a renal pelvis of at least 10 mm after birth and excluded cases based on VUR.[11]

Similar to other reports, we found that congenital hydronephrosis was the commonest renal anomaly detected prenatally.[1,11,12] Variable cut-off points of AP dilatation have been used by previous studies, which include 4 to 10 mm in the second trimester, and 7 to 10 mm in the third trimester, with a lower rate of false positive readings with higher cut-off points.[12] In our study, the use of a 5-mm cut-off point at any time during the pregnancy resulted in false positive rate of 26.7%, as the anomaly was shown to disappear at the first postnatal US. Considering the limitation of health services in the developing world, we consider that a lower cut-off point would probably be more appropriate in these countries.

The availability and accuracy of US screening is variable as this examination is commonly carried out by experienced staff in large cities. This is, unfortunately, not the case in rural areas and small cities where US availability and accuracy are limited. A study from Riyadh reported that the antenatal detection rate of PUV was only 27%, which is significantly less than the international rate of 70%, despite the fact that most antenatal follow-ups were performed in referral centers in the capital city.[13] A study from Qatar using 4 mm as the cut-off point in 311 babies resulted in 45 (14.4%) cases that needed operative interventions.[14] Therefore, high false positive results antenatally, which could be excluded by US postnatally, could be recommended. However, only an AP diameter of 10 mm or more after 24 weeks postnatally is considered as abnormal by many investigators.[12,15,16] At present, an AP diameter of 5 mm is still recommended by other investigators as a cut-off point after 20 weeks,[3,17] particularly as it was shown that this approach will result in early postnatal management of affected infants and prevent frequent urinary tract infections and nutritional disturbances, enabling normal growth.[17,18]

In the current study, the variation in the timing of the first postnatal US was as a result of lack of consensus among the neonatologists about the importance and timing of US in babies with antenatally diagnosed congenital hydronephrosis. More so, a considerable number of patients were lost to follow-up, which highlights the need to perform the first postnatal US before the children are discharged from hospital. Therefore, it was recommended by Docimo et al. that an early US should be performed in children with ADUTA within the first 48 hours of life.[19] Wiener et al reported that an initial ultrasound within 48 hours after birth underestimated the degree of hydronephrosis compared to scans at 7 to 10 days, but this difference was not clinically significant.[20] The majority of resolved hydronephrosis occurred within the first 2 months in this study, which was similar to previous reports.[1,2,5] We also found children in which the hydronephrosis resolved up to 1 year after birth, which indicates the need for further investigations, such as MCUG and nuclear scans, to be delayed, unless the AP pelvic diameter postnatally is 10 mm or more.

We found that postnatal US was the best predictor of significant underlying structural abnormalities. Similar results were obtained by Gokce et al from Istanbul who studied 256 babies and concluded that the natural history and outcome of infants with ADUTA could be identified based on postnatal US parameters.[18] Previous reports from Europe showed slight regional variations in the prevalence of postnatally diagnosed cases.[9] Postnatal US is also a measure of gross renal parenchyma, and it is helpful in defining renal hypoplasia.[21]

We observed that nonresolution of hydronephrosis was associated with an AP diameter of 9 mm or more on the first postnatal US. We suggest that all babies with antenatal hydronephrosis should have an early postnatal scan if the AP diameter ranges from 5 to 9 mm, with a follow-up US within 4 to 8 weeks. If the AP diameter is 10 mm or more, then further investigations for underlying anatomical anomalies are warranted.

We detected cystic changes or other anomalies, such as duplex kidneys antenatally in a small percentage of children. Renal duplex anomalies as well as renal cystic anomalies can be accurately diagnosed by prenatal sonography.[22] The antenatal detection of all renal anomalies is important as it allows planning of postnatal care and hence may help prevent urinary tract infections and renal function impairment.[18,23]

In conclusion, congenital hydronephrosis is the commonest antenatally detected renal anomaly. A large percentage (more than a fourth of the cases) resolved within 2 months of birth, but underlying anatomical abnormalities was found in 12.1% of cases. All babies with antenatally detected hydronephrosis should be examined postnatally by US within 48 hours of birth, but further radiological investigations should only be performed for cases with persistent significant (>10 mm) AP dilatation.

Acknowledgments

This project was funded by the Deanship of Scientific Research (DSR), King AbdulazizUniversity, Jeddah, under the grand number (432/003/d) for Pediatric Nephrology research. The authors, therefore, acknowledge the DSR technical and financial support. The authors also thank the clinical research unit at KAUH for their assistance with the statistics and writing up this paper.

REFERENCES

1. Mallik M, Watson AR. Antenatally detected urinary tract abnormalities: more detection but less action. Pediatr Nephrol 2008 Jun;23(6):897-904.
2. Becker AM. Postnatal evaluation of infants with an abnormal antenatal renal sonogram. Curr.Opin. Pediatr 2009 Apr;21(2):207-13.
3. Valent-Moric B, Zigman T, Cuk M, Zaja-Franulovic O, Malenica M. Postnatal evaluation and outcome of infants with antenatal hydronephrosis. Acta Clin.Croat. 2011 Dec;50(4):451-5.
4. Cachat F, Ramseyer P, Meyrat BJ, Frey P, Boubaker A, Lepori D, Parvex P, Bugmann P, Girardin E. [Antenatally detected hydronephrosis: practical approach for the pediatrician]. Rev.Med.Suisse 2005 Feb 16;1(7):505-12.
5. Moorthy I, Joshi N, Cook JV, Warren M. Antenatal hydronephrosis: negative predictive value of normal postnatal ultrasound--a 5-year study. Clin. Radiol. 2003 Dec;58(12):964-70.
6. Ismail A, Elkholy A, Zaghmout O, Alkadhi A, Elnaggar O, Khairat A, Elhassanat H, Mosleh A, Hamad B, Elzomer J, et al. Postnatal management of antenatally diagnosed ureteropelvic junction obstruction. J.Pediatr Urol. 2006 Jun;2(3):163-8.
7. Chertin B, Pollack A, Koulikov D, Rabinowitz R, Shen O, Hain D, Hadas-Halpren I, Shenfeld OZ, Farkas A. Long-term follow up of antenatally diagnosed megaureters. J.Pediatr Urol. 2008 Jun;4(3):188-91.
8. Dudley JA, Haworth JM, McGraw ME, Frank JD, Tizard EJ. Clinical relevance and implications of antenatal hydronephrosis. Arch.Dis.Child Fetal Neonatal Ed 1997 Jan;76(1):F31-F34.
9. Raboei E, bou-Seoud M, bou-Nassef N, Mehboob F, Saggaf A, Luoma R. Prenatal ultrasound screening of the urinary tract is useful. Pediatr Surg.Int. 2002 Sep;18(5-6):432-4.
10. Garne E, Loane M, Wellesley D, Barisic I. Congenital hydronephrosis: prenatal diagnosis and epidemiology in Europe. J.Pediatr Urol. 2009 Feb;5(1):47-52.
11. Woodward M, Frank D. Postnatal management of antenatal hydronephrosis. BJU.Int. 2002 Jan;89(2):149-56.
12. Toiviainen-Salo S, Garel L, Grignon A, Dubois J, Rypens F, Boisvert J, Perreault G, Decarie JC, Filiatrault D, Lapierre C, et al. Fetal hydronephrosis: is there hope for consensus? Pediatr Radiol. 2004 Jul;34(7):519-29.
13. Neel KF, El-Faqih SR, de CR, bu Daia JM, Al-Shammari AM, Al-Jasser A, Al-Farraj H. Presentation of Posterior Urethral Valves in Saudi Arabia in the 90's. Saudi J.Kidney Dis.Transpl. 2001 Oct;12(4):516-9.
14. Saad TS, Al-Zamer J, Al-Thani GM, Al-Khateeb D, Salman M. Outcome of congenital hydronephrosis in qatar. Saudi J.Kidney Dis.Transpl. 1998 Oct;9(4):430-4.
15. Grignon A, Filion R, Filiatrault D, Robitaille P, Homsy Y, Boutin H, Leblond R. Urinary tract dilatation in utero: classification and clinical applications. Radiology 1986 Sep;160(3):645-7.
16. Fernbach SK, Maizels M, Conway JJ. Ultrasound grading of hydronephrosis: introduction to the system used by the Society for Fetal Urology. Pediatr Radiol. 1993;23(6):478-80.
17. Yavascan O, Aksu N, Anil M, Kara OD, Aydin Y, Kangin M, Cetinkaya E, Bal A. Postnatal assessment of growth, nutrition, and urinary tract infections of infants with antenatally detected hydronephrosis. Int.Urol.Nephrol 2010 Sep;42(3):781-8.
18. Gokce I, Biyikli N, Tugtepe H, Tarcan T, Alpay H. Clinical spectrum of antenatally detected urinary tract abnormalities with respect to hydronephrosis at postnatal ultrasound scan. Pediatr Surg.Int. 2012 May;28(5):543-52.
19. Docimo SG, Silver RI. Renal ultrasonography in newborns with prenatally detected hydronephrosis: why wait? J.Urol. 1997 Apr;157(4):1387-9.
20. Wiener JS, O'Hara SM. Optimal timing of initial postnatal ultrasonography in newborns with prenatal hydronephrosis. J.Urol. 2002 Oct;168(4 Pt 2):1826-9.
21. Farhat W, McLorie G, Bagli D, Khoury A. Greater reliability of neonatal ultrasonography in defining renal hypoplasia with antenatal hydronephrosis and vesicoureteral reflux. Can.J.Urol. 2002 Feb;9(1):1459-63.
22. Adiego B, Martinez-Ten P, Perez-Pedregosa J, Illescas T, Barron E, Wong AE, Sepulveda W. Antenatally diagnosed renal duplex anomalies: sonographic features and long-term postnatal outcome. J.Ultrasound Med. 2011 Jun;30(6):809-15.
23. Wiesel A, Queisser-Luft A, Clementi M, Bianca S, Stoll C. Prenatal detection of congenital renal malformations by fetal ultrasonographic examination: an analysis of 709,030 births in 12 European countries. Eur.J.Med.Genet. 2005 Apr;48(2):131-44.