

Indications for enucleation and evisceration in a tertiary eye hospital in Riyadh over a 10-year period

Saad A. Al-Dahmash, Sawsan Saad Bakry, Nada H. Almadhi, Lolwah M. Alashgar

From the Department of Ophthalmology, College of Medicine, King Saud University, Riyadh, Saudi Arabia

Correspondence: Dr. Saad A. Al-Dahmash · Department of Ophthalmology, College of Medicine, King Saud University, PO Box 240310, Riyadh 11322, Saudi Arabia · T:+966114786100 Ext.1426, F:+9664775731 · dr_dahmash@yahoo.com ORCID: <http://orcid.org/0000-0002-9326-0172>

Ann Saudi Med 2017; 37(4): 313-316

DOI: 10.5144/0256-4947.2017.313

BACKGROUND: Enucleation and evisceration are eye removal procedures considered as palliative treatment when all other therapeutic options are exhausted.

OBJECTIVE: Describe the causes and histopathological findings leading to enucleation/evisceration, and correlate the clinical findings with the histopathological findings.

DESIGN: Retrospective, descriptive study.

SETTINGS: Tertiary care hospital, Riyadh, Saudi Arabia.

PATIENTS AND METHODS: The medical records of patients who underwent enucleation or evisceration from February 2005 to May 2015 were reviewed. Patients were classified into two categories based on indications of surgery: traumatic and nontraumatic. Causes of ocular injury in the traumatic group were documented, and the histopathological findings were reviewed for the nontraumatic cases.

MAIN OUTCOME MEASURE(S): Number of enucleation and evisceration surgeries and their causes and histopathological findings.

RESULTS: One hundred ten patients underwent evisceration (n=69, 63%) and enucleation (n=41, 37%). Causes were traumatic in 38 (35%) and nontraumatic in 72 (65%). The median age was 50 years and there were 64 men and 46 women. Postoperative endophthalmitis was the most common indication for surgery (n=24, 21.8%), followed by painful blind eye (n=22, 20%). Ocular trauma was more predominant in men (n=29, 76%) than in women (n=9, 24%), and the leading mechanism of trauma was metallic nail injuries (n=6, 15.8%). In the nontraumatic group, endophthalmitis was the most common histopathological finding (n=25, 34.7%).

CONCLUSIONS: The majority of the eye enucleation/evisceration surgeries were due to nontraumatic causes, especially postoperative infections. However, severe eye trauma was still a main indication for this destructive procedure. Guidelines are needed to decrease the incidence/severity of work-related eye injuries and to detect and manage eye infections earlier and more promptly.

LIMITATIONS: Retrospective study, in one hospital in one area; therefore, results cannot be generalized.

Enucleation and evisceration are eye removal procedures considered as palliative treatment when all other therapeutic options are exhausted.^{1,2} Enucleation is the removal of the whole intact eyeball, cutting the six extraocular muscles and transecting the optic nerve with conservation of the conjunctiva.² Evisceration is the removal of the eye content through

a corneal incision, leaving the scleral shell, conjunctiva, extraocular muscles, orbital fat and the optic nerve; it is considered a cosmetic procedure.² Both procedures result in an anophthalmic socket. Enucleation and evisceration are used to treat numerous ocular conditions, trauma being the most common predisposing factor according to Yousuf et al and Ababneh et al.^{3,4} Other

conditions managed by such surgeries include intraocular infection (endophthalmitis) and phthisis bulbi. Malignant intraocular tumors such as melanomas and retinoblastomas are managed by enucleation only to prevent tumor spread into the orbital cavity.³⁻⁵ In a review of 3264 enucleated globes over 60 year period, Setlur et al found that glaucoma was the most common indication for an enucleation procedure during the 1950s (12 globes, 23%). By the 2000s there were no cases caused by glaucoma, while neoplastic causes accounted for 21% (79 globes) in the 1950s and 51% (141 globes) in the 2000s.⁶ There has been a decrease in enucleation procedures and changes in the indication mostly due to improvement of medical and surgical procedures. Yet, there had been no decrease in cases due to neoplasm despite the introduction of new chemotherapeutic agents and radioactive plaque therapy.⁶ Similarly, Saeed et al reported that trauma, endophthalmitis and malignant melanoma are the commonest histopathological causes for both procedures in the period 1994-2003.⁷ However, the causes of enucleation/visceration surgeries and their indications vary from one country to another, and from one decade to the next.⁵⁻¹⁵ Due to the scarcity of data in our region, this retrospective study was mainly conducted to determine the indications, underlying causes, histopathological findings of visceration and enucleation procedures performed at King Abdul-Aziz University Hospital in Riyadh, Saudi Arabia. Describing these outcomes should help to establish guidelines for treatment and preventative measures.

PATIENTS AND METHODS

A retrospective study was conducted using the medical records of all the visceration and enucleation procedures documented in the Department of Ophthalmology in King Abdulaziz University Hospital in Riyadh, between February 2005 and May 2015, after obtaining institutional review board approval. We retrieved the following information: demographic information, clinical history, visual acuity, indication for surgery and histopathological findings. Patients were stratified into two categories based on indications of surgery: traumatic and nontraumatic.

RESULTS

Of 110 eyes of 110 patients (64 men and 46 women), 69 eyes (63%) were viscerated and 41 eyes (37%) were enucleated. The median age was 50 years. The mean (SD) age was 54 (26) years and 50% (n=36) were non-Saudi patients. The youngest was 2 months old and the oldest was 91 years old. The majority of patients had a

visual acuity of light perception or none at the time of surgery (n=90, 82%).

The majority of surgeries were nontraumatic (n=72, 65.5%). In the nontraumatic group, endophthalmitis, painful blind eye, disfiguring eye, malignancies and corneal pathologies were indications (**Table 1**). Disfiguring (phthisis) blind eye was the most common indication for surgeries in the traumatic group (17.3%), while postoperative endophthalmitis was the most common in the nontraumatic group (21.8%). Sixty-four of the viscerated/enucleated eyes in the nontraumatic group were sent for histopathology. The most common histopathological diagnosis was endophthalmitis (34.7%) (**Figure 1**). In the traumatic group, disfiguring blind eye (phthisis) was the most common indication in traumatic surgeries (17.3%) followed by painful blind eye, traumatic endophthalmitis and prevention of sympathetic ophthalmia. The leading cause was metallic nail injuries during hammering mainly in construction workers (15.8%), followed by falls on sharp objects (13.2%), and stone injuries (13.2%) (**Table 2**).

The frequency of visceration/enucleation due to nontraumatic causes was about the same by gender (n=35, 49% in men and n=37, 51% in women). However, visceration/enucleation caused by eye trauma (n=38, 34.5%) occurred more commonly in men (n=29, 76%) men than in women (n=9, 24%). For traumatic causes, the mean (SD) age was younger than for nontraumatic causes 36 (18) years vs 53 (28) years. Traumatic injuries were more common in non-Saudi laborers 63% (n=24).

Table 1. Indications for enucleation/visceration in non traumatic and traumatic groups (n=110).

Indication	n (%)
Nontraumatic	72 (65.5)
Postoperative endophthalmitis	24 (21.8)
Painful blind eye	22 (20)
Ocular tumors	15 (13.6)
Disfigured (phthisis) blind eye	7 (6.4)
Corneal (severe keratitis or melting/perforation in blind eye)	4 (3.6)
Traumatic	38 (34.5)
Disfigured (phthisis) blind eye	19 (17.3)
Painful blind eye	9 (8.2)
Endophthalmitis	7 (6.4)
Prevention of sympathetic ophthalmia	3 (2.7)

DISCUSSION

Although removal of the eye (enucleation/evisceration) has been a common practice for end-stage eye diseases in the past, there has been a decreasing trend in this choice of surgery over the last two decades. In our study, the three most common indications for eye enucleation/evisceration were postoperative endophthalmitis, nontraumatic blind painful eye, and traumatic disfigured eyes, which are similar to common indications in some developed countries (United States, Denmark).^{3,8} The median age of eye enucleation/evisceration in our population was 50 years, which is close to that in developed nation, and older than some of the developing countries.^{3-4,6,8-12,16} A traumatic indication for enucleation/evisceration was more common in men than in women, a finding similar to most of the published literature because men are more prone to trauma.^{3-4,8-17} The evisceration procedure was more common in our series, which reflects the low incidence of malignant intraocular tumors, especially the choroidal melanoma in our non-Caucasian population, where enucleation is more often the procedure for advanced stages of intraocular malignancies.^{1,3-12,14-16}

In an article on work-related eye injuries in Thailand, Chaikitmongkol and coauthors reported that the most common ocular trauma was injury from metallic nails, which is similar to our series where most of the trauma was work-related metallic nailing.¹⁸ Lundin and colleagues in a series of ocular trauma cases ending in enucleation, reported that the most common mechanisms of injury were gunshots, outdoor or recreational activities, falls, non-motor vehicle accidents, motor vehicle accidents, work-related injury, and sports-related injury.¹⁹ Bauza and coworkers reported the nail gun as the most frequent form of trauma in work-related open-globe injuries.²⁰ Kitzmann and colleagues reported the commonest pathological findings as intraocular tumors (48.2%), end-stage glaucoma (12.8%), phthisis bulbi (11.7%), trauma (11.3%), chronic retinal detachment (8.6%), and infectious-inflammatory causes (7.1%) in 646 consecutive surgical eye specimens.¹⁴

In conclusion, the majority of eye enucleation/evisceration surgeries were due to nontraumatic causes especially postoperative infections. However, severe eye trauma was still a main indication for this destructive procedure. Guidelines are needed to decrease the incidence of postoperative endophthalmitis such as using prophylactic intracameral antibiotics after cataract surgery. Guidelines are also needed to detect and manage endophthalmitis earlier and more promptly by increasing the awareness of general ophthalmologists to the early signs and symptoms and stressing

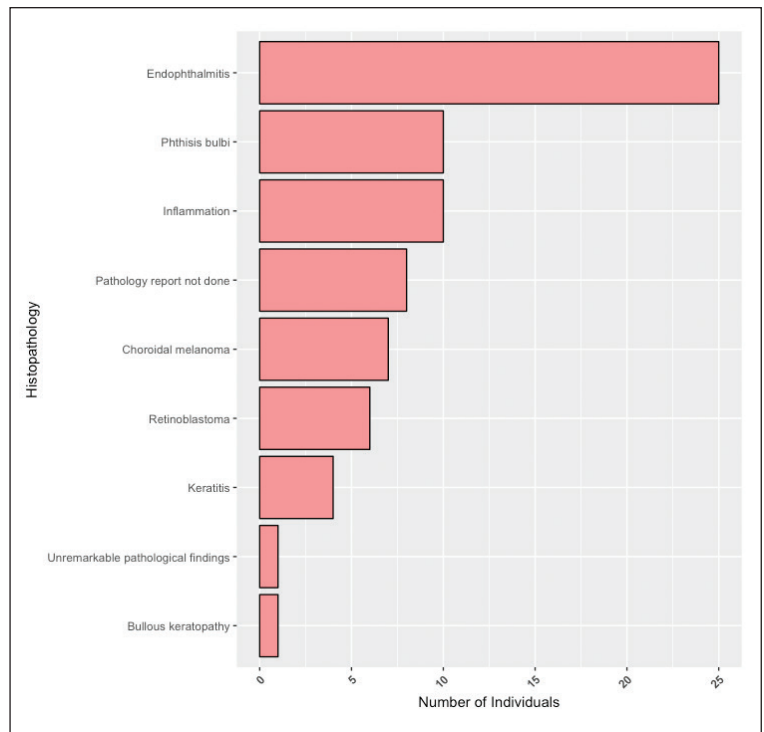


Figure 1. Histopathological findings for enucleation/evisceration in nontraumatic group (n=72).

Table 2. Causes of ocular injury in traumatic group (n=38).

Causes	n (%)
Metal nail	6 (15.8)
Fall on sharp object	5 (13.2)
Stone	5 (13.2)
Drill	2 (5.3)
Fist	2 (5.3)
Gunshot	2 (5.3)
Road traffic accident	2 (5.3)
Sharp object	2 (5.3)
Wooden stick	2 (5.3)
Car handle	1 (2.6)
Explosion	1 (2.6)
Knife	1 (2.6)
Metallic spring	1 (2.6)
Not recorded	6 (15.9)

the importance of immediate initiation of treatment to prevent progression to the blind stage that requires enucleation/evisceration surgery. Also, it is important for employers to apply safety measures, such as obligatory use of protective eye glasses, at construc-

tion projects to minimize the incidence of work-related eye injuries.

Conflict of interest

The authors report no conflict of interest.

REFERENCES

- O'donnell, B., Kersten, R., McNab, A. and Rose, G. (2005) 'Enucleation versus evisceration', *Clinical & Experimental Ophthalmology*, 33(1), pp. 5-9.
- Kanski, J., Bowling, B. (2011) *Kanski's Clinical Ophthalmology*, 7th edn. London United Kingdom: Elsevier Health Sciences.
- Yousuf SJ, Jones LS & Kidwell ED., Jr (2012) Enucleation and evisceration: 20 years of experience. *Orbit*. 31:211-5.
- Ababneh, O., AboTaleb, E., Abu Ameerh, M., & Yousef, A. (2015). Enucleation and evisceration at a tertiary care hospital in a developing country. *BMC Ophthalmology*, 15, 120.
- Soares IP, Frana VP. (2010) 'Evisceration and Enucleation', *Seminars in Ophthalmology*, 25(3), pp. 94-97.
- Setlur, V., Parikh, J. and Roa, N. (2009) 'Changing causes of enucleation over the past 60 years', *Graefe's Arch Clin Exp Ophthalmol*, 248(417), pp. 593-597.
- Saeed MU, Chang BY, Khandwala M, Shivane AG, Chakrabarty A. (2006) Twenty year review of histopathological findings in enucleated/eviscerated eyes. *J Clin Pathol* 59(2), pp. 153-155
- Rasmussen ML, Prause JU, Johnson M, Kamper-Jorgensen F, Toft PB. (2010) Review of 345 eye amputations carried out in the period 1996-2003, at Rigshospitalet, Denmark. *Acta ophthalmol* 88(2), pp. 218-221
- Geirsdottir A, Agnarsson BA, Helgadóttir G, Sigurdsson H. (2014) Enucleation in Iceland 1992-2004: study in a defined population. *Acta ophthalmol* 92(2), pp. 121-125
- Gyasi, M., Amoaku, W. and Adjuik, M. (2009) 'Causes and incidence of destructive eye procedures in north-eastern Ghana', *Ghana Med J*, 43(3), pp. 122-126.
- Tajunisah I, Reddy SC, Mas-Ayu S. (2008) Study of the indications and changing trends of enucleation and evisceration in West Malaysia. *Int J Ophthalmol* 1(2), pp. 161-164
- Keenan, T. D. L., & Sargent, N. J. (2011). Enucleation and Evisceration in the Palestinian Territories. *Middle East African Journal of Ophthalmology*, 18(2), pp. 170-172.
- Kord Valeshabad, A., Naseripour, M., Asghari, R., Parhizgar, S. H., Parhizgar, S. E., Taghvaei, M., & Miri, S. (2014). Enucleation and evisceration: indications, complications and clinicopathological correlations. *International Journal of Ophthalmology*, 7(4), pp. 677-680.
- Kitzmann, A., Weaver, A., Lohse, C., Buettner, H. and Salomo, D. (2003) 'Clinicopathologic Correlations in 646 Consecutive Surgical Eye Specimens, 1990-2000', *Am J Clin Pathol*, 119(4), pp. 594-601
- Knezevi, M., Paovi, J. and Sredojevi, V. (2013) 'Causes of eye removal - Analysis of 586 eyes', *Vojnosanit Pregl*, 70(1), pp. 26-31.
- Kagmeni G, Noche CD, Nguéfack-Tsague G, Wiedemann P. Indications for surgical removal of the eye in rural areas in Cameroon. *Ophthalmol Eye Dis* 2014; 6: 27-30.
- Koylu M, Gokce G, Uysal Y, Ceylan O, Akincioglu D, Gunal A. Indications for Eye Removal Surgeries: A 15-Year Experience at a Tertiary Military Hospital. *Saudi Med J* 2015; 36 (10):1205-1209.
- Chaikitmongkol V, Leeungurasatien T, Sengupta S. Work-Related Eye Injuries: Important Occupational Health Problem in North Thailand. *Asia Pac J Ophthalmol (Phila)*. 2015 May-Jun;4(3):155-60.
- Lundin AM, Azari AA, Kanavi MR, Potter HD, Lucarelli MJ, Burkat CN, Albert DM. Ocular Trauma Resulting in Enucleation: A 12-Year Experience from a Large Regional Institution. *WOMJ*. 2014 Jun;113(3):99-101.
- Bauza AM, Emami P, Son JH, Langer P, Zarbin M, Bhagat N. Work-Related Open-Globe Injuries: Demographics and Clinical Characteristics. *Eur J Ophthalmol*. 2013 Mar-Apr;23(2):242-8.